



PATIENT

Molly Churchill

SPECIES

Canine

BREED

Labrador Retriever

SEX

Female Spayed

AGE

11 years

WEIGHT

93lbs

INTERPRETED BY

Maggie Machen Lamy,
DVM, DACVIM
(Cardiology)

IMAGING PERFORMED BY

Diane McFadden

HOSPITAL NAME

Tranquility Veterinary
Clinic

REFERRING VET

Dr. Christensen

INVOICE

25147

DATE

7/5/22

PRESENTING CLINICAL SIGNS

History: Panting. Lethargic. Hypertension.

-Current medications: On enalapril 20mg BID, Telmisartan 60mg SID, galliprant 40mg SID.

-Abnormal PE/Chem/CBC/UA Results: Elevated ALKP, mild anemia.

ECHOCARDIOGRAM FINDINGS

2D, m-mode, color flow and doppler imaging is available. Mild diffuse thickening of mitral valve leaflets with no prolapse into the left atrial lumen. Mild eccentric mitral regurgitation with no left atrial dilation. Normal LV diameter with adequate myocardial function. The tricuspid valve appears normal with no tricuspid regurgitation. Normal right atrial and ventricular diameter and morphology indicating no overt evidence of pulmonary arterial hypertension. The pulmonic and aortic valves are normal in morphology and mobility. Normal pulmonic and mildly elevated aortic outflow velocities with laminar flow. No obvious aortic or pulmonic insufficiency. No pericardial or pleural effusion noted. No obvious cardiac masses.

CARDIAC CHART

CANINE CARDIAC PARAMETERS	MR VMAX (m/s)	TR VMAX (m/s)	LA/AO (Boon method)	LA/AO (Heart Base; Swe)	FS (%)	EF (%)	EPSS (cm)
NORMAL PARAMETER	4.5-5.5	<2.7	1.3	<1.6	28-40	40-100	<0.6
PATIENT	NM	NA	1.3	1.3	34	63	0.4
CANINE CARDIAC PARAMETERS	HR (BPM)	AV VMAX (m/s)	PV MAX (m/s)	BODY WEIGHT (kg)	LA 2D short axis Base view (cm)	LVIDd Avg; 2D and m-mode short axis (cm)	LVIDs Avg; 2D and m-mode short axis (cm)
NORMAL PARAMETER	50-100	0.7-1.7	0.7-1.6	BELOW	BELOW	BELOW	BELOW
PATIENT	120	2.5	1.7	42.2	3.3	4.5	3.0
*Normal chamber parameters expressed as a mean value (SD)							
BODY WEIGHT DEPENDENT PARAMETERS							
<i>*Note: All measurements based upon multi-modal images and methods. An average value is reported.</i>							
	5	1.40 (4.5)	2.74 (5.2)	1.60 (4.7)			
	10	1.50 (3.8)	3.27 (3.5)	2.06 (3.1)			
	15	1.83 (2.0)	3.71 (2.4)	2.43 (2.1)			
	20	2.02 (1.9)	4.14 (2.2)	2.80 (2.0)			
	25	2.18 (2.4)	4.48 (2.9)	3.10 (2.5)			
	30	2.33 (3.3)	4.83 (3.9)	3.39 (3.4)			
	35	2.48 (4.3)	5.17 (5.0)	3.69 (4.5)			
	40	2.62 (5.2)	5.48 (6.1)	3.96 (5.4)			
	50	2.88 (7.1)	6.07 (8.3)	4.46 (7.4)			

INTERPRETATION OF THE FINDINGS & FURTHER RECOMMENDATIONS

Chronic degenerative valve disease causing mild mitral regurgitation. Lack of significant left atrial enlargement indicates the current risk for complication is low. A mildly elevated aortic outflow velocity is noted, which is a benign finding that may contribute to murmur intensity. No additional issues are noted and there is no evidence of chronic systemic hypertension. Occasional premature beats are noted throughout the study and an ECG is strongly recommended.

These findings do not explain panting or lethargy and full systemic evaluation is advised. Additionally, no comment can be made on systemic hypertension without further information.



PATIENT

Molly Churchill

SPECIES

Canine

BREED

Labrador Retriever

SEX

Female Spayed

AGE

11 years

WEIGHT

93lbs

INTERPRETED BY

Maggie Machen Lamy,
DVM, DACVIM
(Cardiology)

IMAGING PERFORMED BY

Diane McFadden

HOSPITAL NAME

Tranquility Veterinary
Clinic

REFERRING VET

Dr. Christensen

INVOICE

25147

DATE

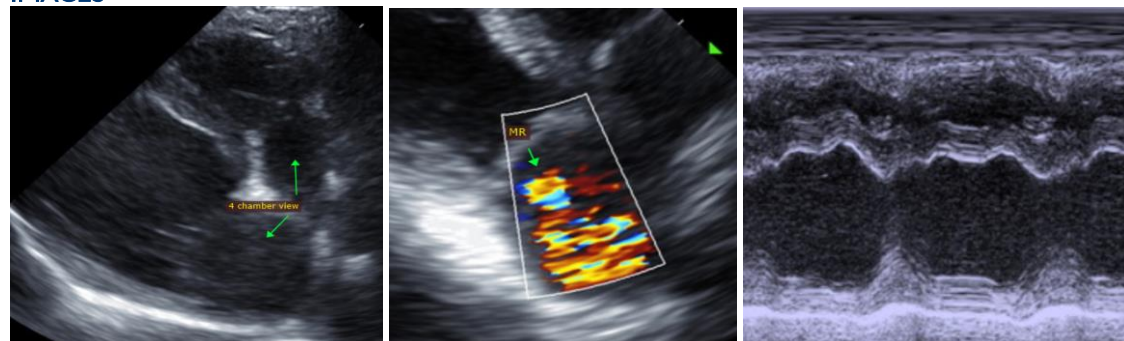
7/5/22

In a dog with no significant left atrial enlargement, no cardiac medications are clearly indicated. Assessment of progression in the future will help predict long term prognosis, which is highly variable at this stage (B1). Omega fatty acid supplementation and mild salt restriction may be of some long-term benefit. Monitor for development of a cough, labored breathing, exercise intolerance or collapse episodes.

Anesthetic risk is considered mild if needed. Cardiac protective drug choices (opioid/benzodiazepine premedication, propofol or alfaxalone induction, isoflurane gas) are recommended. Pre-oxygenate for 5-10 minutes prior to induction. Monitor for arrhythmias, hypotension, and hypoxia both intra and post-operatively and intervene as necessary. Mild IV fluid restriction is recommended to avoid fluid overload. Avoid heart rate stimulating drugs such as atropine unless clinically indicated.

Recommend conservative monitoring with a recheck echocardiogram in 6 months, sooner if any development of clinical signs.

IMAGES



The information and recommendations provided are based on the images presented by the referring veterinarian. No evaluation can be communicated regarding pathology that was not visible in the image/video clips provided.

Thank you for this referral. This report was generated using transcription software, and minor dictation errors may be present. If the clinical or image interpretation does not parallel your findings or if I can be of any further assistance, please contact me.

Maggie Machen Lamy, DVM
Diplomate of the American College of Veterinary Internal Medicine (Cardiology)
info@sonopath.com